

# Gallstone Ileus: An Unusual Diagnosis Often Omitted

Riyad Abbas<sup>1</sup>, Maaroufi Fathillah El Karim<sup>1</sup>, Lammat Lhabib<sup>1</sup>, Rabbani Khalid<sup>1</sup>, Louzi Abdelouahed<sup>1</sup>, Finech Bennisser<sup>1</sup>, Nacir Oussama<sup>2</sup>, Ait Errami Adil<sup>2</sup>, Samlani Zouhour<sup>2</sup>, Krati Khadija<sup>2</sup>, Oubaha Soufia<sup>3</sup>

1. *Departement of General surgery, Arrazi hospital, Mohammed VI university medical center, Marrakech 40000, Morocco.*

2. *Departement of Hepato-gastro-enterology, Arrazi hospital, Mohammed VI university hospital center, Marrakech 40000, Morocco.*

3. *Departement of physiology, faculty of medicine, Marrakech 40000, Morocco.*

**Abstract:** Gallstone ileus is a bowel obstruction secondary to gallstone impaction at some point of the gastrointestinal tract due to the existence of a bilioenteric fistula. It is an uncommon cause of small bowel obstruction, accounting for only 1-4% of all intestinal obstructions. In patients with cholelithiasis, only 0.3-0.5% reportedly develops gallstone ileus. We report a patient with gallstone ileus who presented with small bowel obstruction that was initially misdiagnosed. The correct diagnosis was made based on finding an ectopic gallstone and a cholecystoduodenal fistula on computed tomography. We will discuss the contribution of the various paraclinical examinations for his diagnosis.

**Key words:** Gallstone ileus, bowel obstruction, bilioenteric fistula, ectopic, computed tomography.

## 1. Introduction

Gallstone ileus is a rare complication of the cholelithiasis, where it occurs in less than 0.5%. It is defined by a radiological triad (occlusive syndrome, aerobilia and an ectopic location of the calculi) often linked to a bilioenteric fistula.

Intestinal obstruction following the migration of a vesicular calculus through a cholecystojejunal fistula is a less frequent case of gallstone ileus and the reason behind its late diagnosis. Apart from the spontaneous evacuation of a calculus, which is rare and where only small calculi are involved, the treatment is often surgical.

We are reporting a case of small bowel obstruction complicating a vesicular lithiasis that has migrated through a cholecystojejunal fistula. We will discuss the contribution of the various paraclinical examinations in its diagnosis, as well as the particular interest of the

tomodensitometric examination.

## 2. Observation

Ms. S, age 34 years old, had a Mac Burney Appendectomy for acute appendicitis 12 years ago as the main surgical antecedent.

She was admitted to surgical emergencies for an occlusive syndrome made of abdominal pain, bilious vomiting and a late arrest of fecal matters and of gas; the symptoms evolved for 4 days, getting progressively worse.

Interrogation found earlier episodes of intermittent hepatic colics without any other associated signs.

During the clinical examination on admission, the patient was conscious with a stable hemodynamic status and a temperature of 37 °C.

The abdominal examination found a flat abdomen with a bloated stomach; a slight sensitivity without elective point without defense or contracture, the hernia orifices were free and the rectal bulb was empty at the digital rectal examination. Biological examinations showed no particularities.

The plain X-ray (standing) in the emergencies, revealed water-like levels, without any image of

---

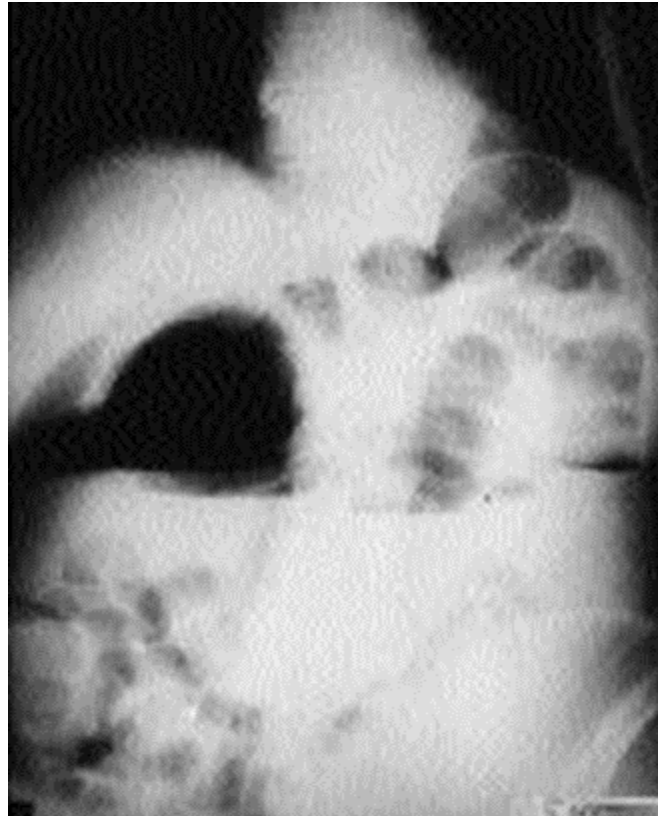
**Corresponding authors:** Riyad Abbas, Departement of General surgery, Arrazi hospital, Mohammed VI university medical center, Marrakech, Morocco. Nacir Oussama, Departement of Hepato-gastro-enterology, Arrazi hospital, Mohammed VI university hospital center, Marrakech, Morocco.

pneumoperitoneum nor calcification detected in projection of the abdominal area (Fig. 1).

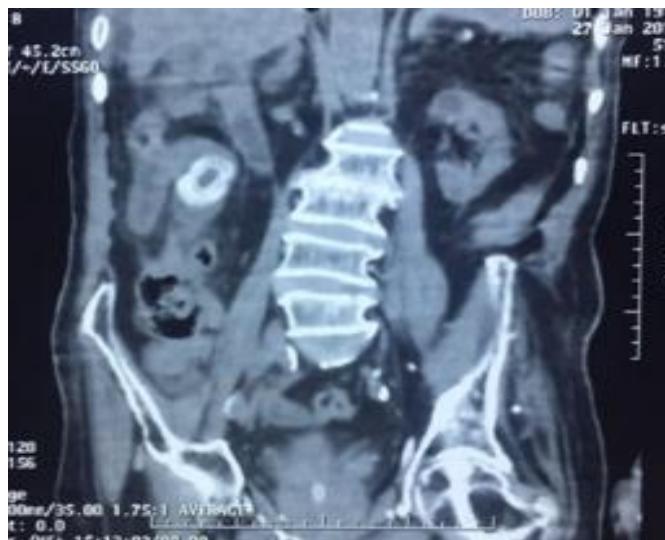To this atypical and unexplained occlusion presentation, a CT-scan was performed, without and after injection of iodinated contrast product; it showed loose hair loops (Fig. 2), an aerobilia, and the presence

of a 4-cm foreign body located in the jejunum (Fig. 3).

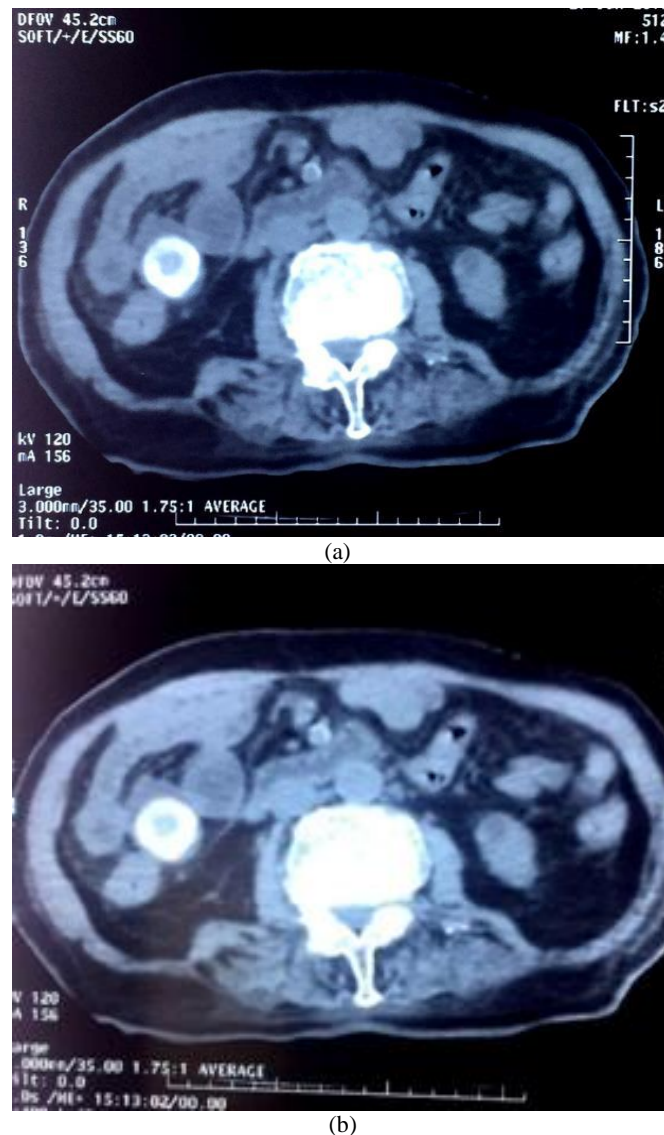The diagnosis of biliary ileus with a small bowel occlusion due to a lithiasic migration to the jejunum through a cholecystojejunalfistula was confirmed. An urgent surgical management was therefore imposed after conditioning. The surgical exploration through a



**Fig. 1** Plain X-ray of the abdomen: air-fluid levels.



**Fig. 2** Abdominal-pelvic CT scan without injection of contrast agent: gray loops distended upstream of a calculus.



**Fig. 3** (a) Aerobilia (pneumobilia) and (b) jejunal calculus (stone in the jejunum).

median incision on the umbilicus revealed the distention of the second pelvic loop, confirmed the presence of the cholecystojejunal fistula, and revealed the presence of two obstructive calculi (3 cm wide) at the level of the intestinal lumen without perforation of the small bowel (Fig. 4a).

The surgical procedure consisted of an enterotomy with extraction of the two calculi (Fig. 4b, 5), irrigation and suction. The cholecystectomy was carried in the same operating time. The postoperative immediate follow-ups were simple.

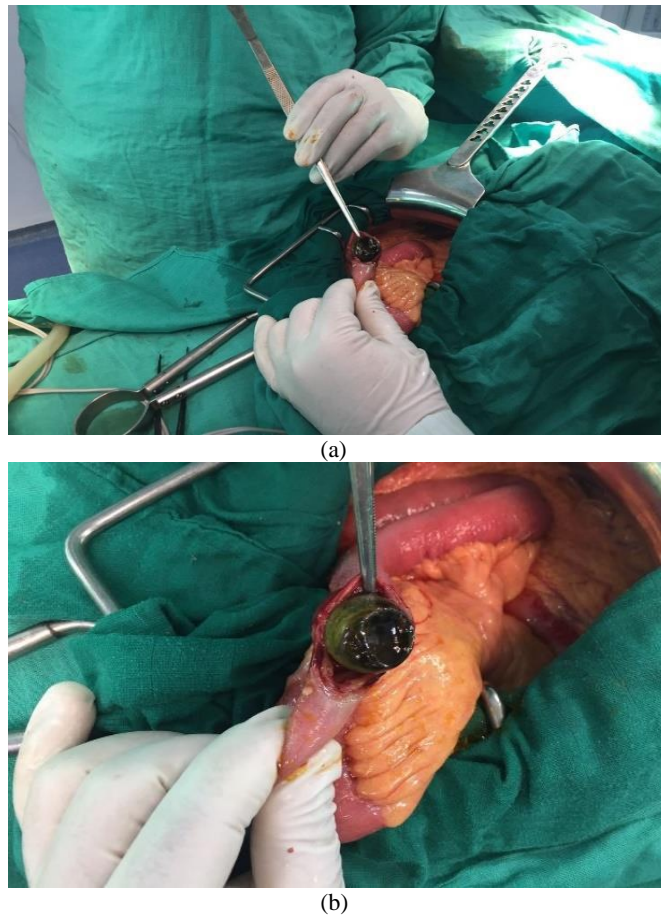
The evolution was favorable, without any special

complication.

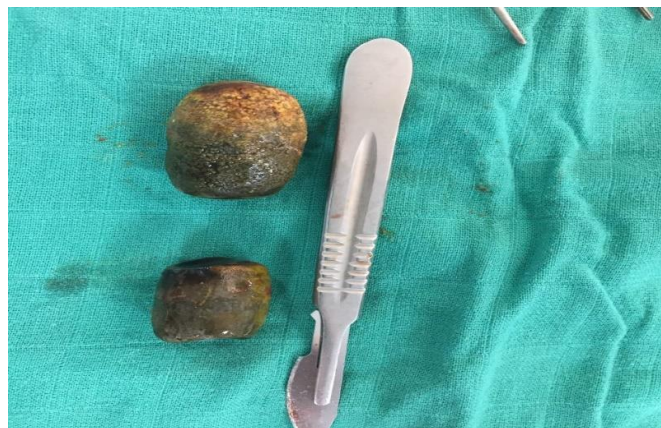### 3. Discussion

Biliary ileus is an intestinal obstruction linked to the migration of a vesicular calculus in the intestinal lumen through a fistula [1]. This situation is due to the progressive erosion of the vesicular wall by this calculus which is too wide to migrate into the biliary system.

It was first described in 1654 by Bartholin [2]. It occurs in 6% to 14% of patients having a biliodigestive fistula [3] and represents 1% to 3% of mechanical organic occlusions [4], but can reach 25% in people of



**Fig. 4 (a) Intraoperative view of an enterotomy and (b) peroperative view (stone in the jejunum).**



**Fig.5 calculi divided into two parts enclosed in the jejunum.**

over 65 years old [5]. This phenomenon is especially visible in women between 70 and 80 years old.

In 80% to 85% of cases, the cause is a bilio-digestive fistula, which in 70% of cases is cholecystoduodenal type [2] followed by cholecystocolic 15% then cholecystocholedoc.

Biliary ileus may also be a complication of the endoscopic sphincterotomy or the result of an intraoperative lithiasis dispersion during a cholecystectomy [6].

The mechanism of fistula formation is due to repeated episodes of cholecystitis lithiasis leading to

chronic inflammation; the serosa of the gallbladder becomes adherent to the serosa of the visceral viscus, leading to local erosion and migration of calculi [7].

The areas closest to the gallbladder, like the duodenum and the right colic angle, are more often interested in the fistulous process: the terminal ileum is the most frequent location obstruction by a gallstone (60% to 70%) [8], because the ileocecal valve is the place of impaction of most calculi regardless of their size [9]. The jejunum is the site in 15% to 20% of cases, and the calculation only affects the duodenal bulb in 10% cases.

Intermittence of symptoms and absence of vesicular history in half of patients make the diagnosis difficult and often late. Preoperatively it is only done in 30% to 55% of cases, when facing the classic triad radiological report attributed to Rigler (1941): aerobilia, mechanical intestinal occlusive syndrome and ectopic location, and a calculus [10]. The plain X-ray can be rather helpful at first in the emergency room, even though this classic triad is only there 25% of the time, apart from the fact that 85% of the vesicular calculi are radiolucent and the aerobilia is inconstant [11]. In our observation, calculi and aerobilia were not seen at the first plain X-ray's interpretation.

The water soluble enema [12] helps to highlight a calculus (be it completely or incompletely obstructive) and to show the existence of a possible fistula on the other hand. In our observation, we have not been able to achieve this considering the emergency of the case and its evolved stage deduced from the clinical picture.

This examination can also be completed by a colonoscopy for the diagnosis of a possible colic calculus. The ultrasound is often not very contributive because of digestive gases. It can sometimes help complete, with the abdomen without preparation the Rigler triad just as to show the hyperechoic image with a cone shadow characteristic of the calculus and a sclero-atrophic gall bladder [13].

Computed tomography seems to be the examination of choice for the preoperative diagnosis of a gallstone ileus [14] with sensitivity, specificity and positive predictive values respectively of 93%, 100% and 99% according to some authors [15]. It is a reliable, fast, and slightly aggressive exam especially in often frail and elderly patients. It shows the calculus, locates it, and shows a minimal arrest of air and fecal matters [16]. In our observation, the location of the fistula was better specified by this examination, as well as the exact location the calculus migrated inside the jejunum. The diagnosis of certainty is made intraoperatively [17].

The treatment of gallstone ileus is often surgical, consisting of lifting the intestinal mechanical obstacle by enterolithotomy, or by a simple colotomy (in case of colic occlusion), as well as a repair of the fistula. This can be done in better conditions if the symptomatology persisted [18].

In fact, the indication of cholecystectomy and the cure of the fistula depend on several factors such as the patient's age and general condition; later on the possibility to realize (or not) other operating acts at the same time or in a second operating time. Cases of spontaneous closure of fistulas have been described [12]; although the existence of a high rate of complications in treated patients simply by enterolithotomy pushes some authors to treat the fistula at the same time [10].

Other therapeutic alternatives have been described in the recent literature: fragmentation of calculations by extracorporeal lithotripsy or by colonoscopy, especially when facing operative contraindications; and the use of coeli-assisted surgery.

The spontaneous expulsion of the calculus remains very rare in the literature. Mortality by the gallstone ileus is still of an average of 14%. Operative mortality is around 13% [19]. The complications are also common (50%): increased by postoperative infections (40%). The recurrence of gallstone ileus occurs in 5 to 9% of cases according to some studies [20].

#### 4. Conclusion

Gallstone ileus is a rare complication (1 to 4 mechanical occlusions) of vesicular lithiasis. It is due to a vesiculoduodenal fistula favoring the passage of a macro-calculus in the small bowel. Occlusion is then caused by the blocking of the calculus at the level of the ileum [5].

The clinical signs are nonspecific. They often lead to a diagnosis delay [1]. The diagnosis is based on the triad of Rigler. Computed tomography is effective in locating the calculus and sometimes the bilio-digestive fistula. The surgical treatment consists of extracting the calculus, with or without a cholecystectomy and a cure of the fistula.

Gallstone ileus is a diagnosis that is often forgotten to think about before any mechanical occlusive syndrome, especially in elderly women over 65 years old.

#### References

- [1] Grumbach, K., Levine, M. S., and Wexler, J. A. 1986. "Gallstone Ileus Diagnosed by Computed Tomography." *J Comput Assist Tomogr* 10:146-8.
- [2] Kunin, N., Morin-Chouarbi, V., Prat-Robillard, N., Verbrackel, L., and Cressy, G. 2004. "Il úsbiliarer é v d é par un calcul rectal." *Gastroenterol Clin Biol*. 28: 1184-2.
- [3] Oikarinen, H., Paivansalo, M., Tikkakoski, T., and Saarela, A. 1996. "Radiological Findings in Biliary Fistula and Gallstone Ileus." *Acta Radiol* 37:917-22.
- [4] Chen-Wang, C., Shou-Chuan, S., Shee-Chau, L., and Cheng-Hsin, C. 2008. "Gallstone Ileus: A Disease Easily Ignored in the Elderly." *Int J Gastenterology* 2(1):18-21.
- [5] Zahid, F.E., Benjelloun, B., Ousadden, A., Mazaz, K., and Taleb, K. 2009. "Gallstone Ileus: An Uncommon Cause of Small Bowel Obstruction: A Case Report." *Cases J*. 14(2):9321.
- [6] Habib, E., Khoury, R., Elhadad, A., Jarno, F., and Diallo, T. 2002. "Complications digestives d'un calculbiliaire perdu pendant une cholécystectomie sous coelioscopie." *Gastroenterol Clin Biol*. 26:930.
- [7] Milson, J. W., and McKeigan, J. M. 1985. "Gallstone Obstruction of the Colon: Report of Two Cases and Review of Management." *Dis Colon Rectum* 28:367-70.
- [8] Garc ía-Mar ín, A., P érez-L ópez, M., P érez-Bru, S., and Compañ-Rosique, A. 2014. "Gallstone Ileus, an Uncommon Cause of Bowel Obstruction." *Revista de Gastroenterolog ía de M éxico* 79(3):211-3.
- [9] Costi, R., Randone, B., Violi, V., Scatton, O., Sarli, L., Soubrane, O., et al. 2009. "Cholecystocolonic Fistula: Facts and Myths: A Review of the 231 Published Cases." *J Hepatobiliary Pancreat Surg*. 16:8-18.
- [10] Tuil, S., Souillac, P., Beroud, P., et al. 1994. "Int é r é t du scanner dans le diagnostic d'il úsbiliaire." *Gastroenterol Clin Biol*. 18:1156-7.
- [11] Swinnen, L., and Sainte, T. 1994. "Colonic Gallstone Ileus." *JBR-BTR* 77:272-4.
- [12] Artu, P., Gury, B., and Eug ène, C. 1995. "La tomodensitom étrie dans le diagnostic d'il úsbiliaire: une nouvelle observation." *Gas-Troenterol Clin Biol*. 19:735-6.
- [13] Loren, I., Lason, A., Nilsson, A., Nilsson, P., and Nirhov, N. 1994. "Gallstone Ileus Demonstrated by CT." *J Comput Assist Tomogr* 18:262-5.
- [14] Yu, C. Y., Lin, C. C., Shyu, R. Y., Hsieh, C. B., Wu, H. S., Tyan, Y. S., et al. 2005. "Value of CT in the Diagnosis and Management of Gallstone Ileus." *World J Gastroenterol* 11:2142-7.
- [15] Muthukumarasamy, G., Venkata, S. P., Shaikh, I. A., Somani, B. K., and Ravindran, R. 2008. "Gallstone Ileus: Surgical Strategies and Clinical Outcome." *J Dig Dis*. 9(3):156-61.
- [16] Prasad, R.M., Weimer, K. M., and Baskara, A. 2017. "Gallstone Ileus Presenting as Intussusception: A Case Report." *International Journal of Surgery Case Reports* 30: 37-9.
- [17] Martin-Perez, J., Delgado-Plasencia, L., Bravo-Gutierrez, A., Burillo-Putze, G., Martinez-Riera, A., Alarco-Hernandez, A., and Medina-Arana, V. 2013. "Gallstone Ileus as a Cause of Acute Abdomen. Importance of Early Diagnosis for Surgical Treatment." *Cirugia Espanola* 91 (8): 485-9.
- [18] Elabsi, M., Amraoui, M., Erroumani, A., and Chkof, M. R. 2007. "Diagnosis and Treatment: Gallstone Ileus." *Digestive and Liver Disease* 39:180-1.
- [19] Deitz, D. M., Standage, B. A., Pinson, C. W., et al. 1986. "Improving the Outcome in Gallstone Ileus." *AJS* 151:572-80.
- [20] Chatterjee, S., Tamonas, C., Goutan, G., and Ambar, G. 2008. "Gallstone Ileus—An Atypical Presentation and Unusual Location." *Int J Surj*. 6(6):e55-6.