

An Example of Apiphytotherapy Studies in Azerbaijan: Herbal

Elnur Eldaroglu Rahimov and Zumrud Alasgar Ahmedova

Apimed Natural Methods Centre, Baku 3137, Azerbaijan

Abstract: Ginger, turmeric, black seed, artichoke leaves, Azerbaijani thistle honey, and BB (bee bread) have a hepatoprotective effect; therefore, they show effective results separately in case of alcohol-dependent and non-alcoholic liver obesity, hepatitis and toxic liver damage. We studied how it can affect liver enzymes and hepatocytes in this group of patients. We took all these natural plants and bee products in the optimal dose required by the body and prepared a paste called Herbal, so that everyday people could eat comfortably as a food supplement, as well as see the therapeutic and prophylactic results. HERBAL paste for liver ingredients: flaxseed, ginger, seed of thistle, powder of yellow ginger, black cumin, and honey. Benefits: Herbal paste prepared based on well-tested recipes improves the function of the liver and gallbladder. As a hepatoprotector, it affects the recovery of liver cells in liver diseases (hepatitis and cirrhosis), spleen disease, bile duct infections, gallstones in gallbladders, inflammatory bowel disease, colitis, cholecystitis. It helps to remove toxic substances while taking medicine (antibiotics, chemotherapy, painkillers, etc.). Side effects: Individual sensitiveness to the contents of the product. Usage: In acute process 1 teaspoon, during chronic diseases 1 dessertspoon twice a day before eating. Results: 48 women and 54 men with the third level of fatty liver dystrophy decreased to the second level (fibrosis did not occur). During the treatment of 114 patients who had an HCV (hepatitis C virus), I used HERBAL paste as a protector for the liver. After the analyses, 24 patients, who had liver cirrhosis ALT (alanine aminotransferase) and AST (aspartate aminotransferase) in the blood reduced twice. Another 81 patients from 90 who had virus had disappeared in blood analyses and in the exogenous factor of liver and GGT in the blood get normal.

Key words: Phytotherapy, Azerbaijani propolis, apitherapy, integrative medicine, liver, thistle, Azerbaijani honey, liver fatty disease, hepatitis, alternative treatment.

1. Introduction

Herbal products have become increasingly popular, especially among those with chronic diseases. Milk thistle honey has been used for hundreds of years by herbalists and physicians alike to treat a wide range of liver pathology, including fatty liver disease, hepatitis, cirrhosis, and to protect the liver from environmental toxins. Today, millions of people consume milk thistle to support healthy liver function. Researchers have focused their efforts towards studying silymarin, a mixture of flavonolignans extracted from milk thistle, as well as the most active ingredient of this extract, silybin. Silymarin and silybin have become some of the most prescribed natural compounds, and the use of

the two names is often interchangeable. However, each has a different clinical purpose, but there are no definitive results in terms of clinical efficacy. Currently, there is no regulation of herbal products such as milk thistle in the United States as they are not considered drugs and are not under the supervision of the US FDA (Food and Drug Administration). Like most herbal products, the FDA does not approve or recommend the usage of milk thistle as a treatment for any medical condition.

Recent studies have focused on the role of milk thistle in treating nonalcoholic fatty liver disease, a common hepatic manifestation of metabolic syndrome. The prevalence of NAFLD (nonalcoholic fatty liver disease) in western countries is approximately 20% to 30%. Currently, there is no consensus approach when it comes to the treatment of NAFLD. Most clinicians

Corresponding author: Elnur Eldaroglu Rahimov, PhD, research fields: phytotherapy, apitherapy.

approach the disease by emphasizing lifestyle modification, including diet, weight loss, and limiting alcohol intake. However, studies suggest milk thistle can exert beneficial effects in patients with NAFLD. Data indicate that silymarin treatment correlated with a reduction in insulin resistance and a significant decrease in fasting insulin levels. Patients treated with 600 mg/day of silymarin for 12 months demonstrated lower fasting insulin levels. A separate clinical trial evaluated the effectiveness of silymarin compared to metformin and pioglitazone in NAFLD patients. Research showed that patients treated with silymarin had significantly lower transaminase levels compared to those treated with metformin or pioglitazone. In a sample of 25 patients, treated for four months with 200 mg silymarin three times a day before meals, there was a significant reduction in blood glucose levels (from 156 ± 46 mg/dL to 133 ± 39 mg/dL), compared to an increase in the placebo-treated group. In the same period, their HbA1c levels also dropped by an average of 1 point. The same group of patients also demonstrated significantly reduced levels of total cholesterol, triglycerides, and LDL. Another study aimed to evaluate the efficacy of combined treatment, which includes vitamin E, silybin, and phospholipids, demonstrating that this complex improves liver damage, especially plasma markers of liver fibrosis, as well as insulin resistance.

NAFLD is known to be the most prevalent hepatic disorder that is characterized by excessive hepatic fat accumulation, in absence of remarkable alcohol consumption. It affected people around the world in range of 25%-30% in developed and 6%-35% in developing countries. Although many aspects of NAFLD pathogenesis are not yet fully understood, metabolic disturbances such as excessive fat accumulation and insulin resistance play an important role in the pathogenesis of NAFLD. In modern medicine, adherence to life style and dietary modification is a first strategy for NAFLD management or/and prevention of disease progression

to cirrhosis and hepatocellular carcinoma. However, many patients fail to comply with the lifestyle modification. Owing to the growing prevalence of NAFLD and paucity of beneficial remedy, a surge of interest to detect novel effective therapy for alleviating or preventing progression of this disease with minimal side effect is required.

In the last decades, growing evidences showed that investigators are interesting to find effective natural alternative therapy in treatment of numerous diseases. Although vary medical plants were used as traditional and self-care, there is lack of sufficient information in efficacy and their possible side-effect on diseases and this issue made it one of the important problems faced by doctors.

Ginger supplementation resulted in a significant reduction in alanine aminotransferase, γ -glutamyl transferase, inflammatory cytokines, as well as the insulin resistance index and hepatic steatosis grade in comparison to the placebo. We did not find any significant effect of taking ginger supplements on hepatic fibrosis and aspartate aminotransferase.

Ginger is the root of *Zingiber officinale* and is one of the most used spices in many countries. Ginger contains active ingredients such as gingerol, shogaol, zingerone and β -bisabolene. In ancient medical practice, ginger was used for treatment of various disorders such as rheumatoid arthritis, neurodegenerative diseases, inflammation and asthma. Previous studies have shown that ginger and its active compounds can exhibit anti-diabetes, anti-cancer and anti-inflammatory properties. It has been shown that ginger extract can exhibit antioxidant activity and reduce the levels of pro-inflammatory biomarkers. Moreover, recent studies on patients with Type II diabetes and hyperlipidemia have shown that ginger can reduce insulin resistance and serum triglyceride concentration [1].

Turmeric (*Curcuma longa*) is a perennial herb belonging to ginger family (Zingiberaceae). The main biological activity of turmeric is related to curcumin

which has commonly been used as curry powder in Asian cuisine. Curcumin has a polyphenol structure and has been traditionally used as a household treatment for various diseases. Several studies suggested that curcumin has antimicrobial, anti-inflammatory, anti-oxidant, immunomodulatory, renoprotective, anti-cancer, hepatoprotective, hypoglycaemic properties which act through signaling pathways and regulating gene expression.

Although a large body of evidence in *in vitro* and animal studies has supported hepatoprotective activity of curcumin, results from single human study have remained inconclusive. Therefore, present review was aimed to provide summary and conclusive result for effect of curcumin/turmeric on NAFLD compared with placebo in adult participants [2]

After 3 months of *N. sativa* treatment, the mean HCV (hepatitis C virus) RNA levels (PCR (polymerase chain reaction)) ($147,028.2 \pm 475,225.6$) significantly decreased relative to their baseline levels ($380,808.7 \pm 610,937$, $p = 0.001$). All cirrhotic patients (compensated and decompensated) showed no change or an improvement in their Child-Pugh score, patients presented with variable Child-Pugh score, yet the proportions' numbers were small for a valid statistical test. There was a significant increase in total protein and albumin levels after treatment. However, there was no significant change in liver enzymes (ALT (alanine aminotransferase) and AST (aspartate aminotransferase)), bilirubin, or INR. Renal function did not show a significant change from baseline. TAC (total antioxidant capacity) showed a significant increase after treatment (1.612 ± 0.56) relative to the baseline values (1.35 ± 0.05 , $p = 0.001$). Hematological functions varied significantly after 3 months of *N. sativa* treatment. There was a significant increase in RBCs ($p = 0.001$) and platelets ($p = 0.004$) and a significant decrease ($p = 0.013$) in white blood cells.

The liver tissue samples of the 0.2 mL/kg CCl_4 group exhibited remarkable damage. Irregularities were observed in the parenchymal structure, and the

classic lobular structure could not be distinguished. In addition, sinusoidal dilation (++), congestion (+), inflammation (++), intense degeneration (+++), vacuolisation, nodular types of cellular damage (+++), pycnotic nuclei of necrotic cells with eosinophilic cytoplasm (+++) and hypertrophic cell structures (+++) were observed. In the recovery group, sinusoidal dilation (+), inflammation (+), congestion (+) and cellular damage (+) were observed. Sinusoidal dilation (+) and congestion (+) were examined in the curative group [3].

The nutritional requirements of honeybees, *Apis mellifera*, are met by the collection of pollen, nectar, and water. Nectar is the primary source of carbohydrates, while pollen provides proteins, lipids, vitamins and minerals. BB (bee bread) is a fermented mixture of plant pollen, honey, and bee saliva that worker bees use as food for larvae, and for young bees to produce royal jelly. Pollen collected by bees is mixed with a small amount of honey and saliva, and packed into the cells of the honeycomb where it undergoes a chemical change to form a product called BB. This mixture undergoes different chemical processes due to the action of distinct enzymes from glandular secretions, microorganisms, moisture and temperature (35-36 °C chamber temperature offspring), allowing the transformation, improvement and preservation of the stored pollen, which is called BB after two weeks of initial storage.

Despite the role of BB as the main source of protein for the bees, its functional properties have been correlated, as well as its flavonoid content, with the BB's floral origin. In particular, BB has demonstrated *in vitro* antibacterial, antioxidant, and antitumor properties. For the last activity, ethanolic extracts were screened against tumor cell lines (human glioblastoma cell line U87MG) and the normal human astroglia cell line SVGp12 (CRL-08621) using *in vitro* assays.

The BB composition varies according to the origin of the pollen but is mainly composed of water,

proteins, carbohydrates, lipids, inorganic elements and various other minor components such as decanoic acid, gamma globulin, nucleic acids, vitamins B and C, pantothenic acid, bioppterin, neopterin, acetylcholine, and reproductive hormones, among others.

The quality information available on the literature for BB remains limited, with few reports on the phenolic composition of this mixture. Some phenolic compounds were previously identified in BB samples from Poland, Russia, Latvia and Georgia. Other reports on BB samples from Spain and Poland mentioned only total phenolics measured by the Folin-Ciocalteu colorimetric assay and did not provide detailed characterization in terms of individual phenolic compounds.

In the present study, five BB samples, collected from *Apis mellifera* hives located in different apiaries near Guba, in the northeast region of Azerbaijan, and one sample of commercial BB were characterized by HPLC-DAD-ESI/MS in terms of their phenolic profile. Furthermore, the samples were screened against different human tumor cell lines, as well as against non-tumor liver cells [4].

2. Methods

PubMed, Scopus, Web of Science and Google Scholar were systematically searched until December 2017. We included RCTs (randomized controlled trials) which examined effect of curcumin/turmeric supplementation on NAFLD in adult participants. Main outcome was ALT (alanine aminotransferase) and AST (aspartate aminotransferase). ROB (Potential risks of bias) were assessed by using Cochrane ROB tool.

Thirty patients with HCV infection, who were not eligible for IFN/ribavirin therapy, were included in the present study. Inclusion criteria included: patients with HCV with or without cirrhosis, who had a contraindication to IFN- α therapy, or had refused or had a financial constraint to IFN- α therapy. Exclusion criteria included: patients on IFN- α therapy, infection

with hepatitis B or hepatitis I virus, hepatocellular carcinoma, other malignancies, major severe illness, or treatment non-compliance. Various parameters, including clinical parameters, complete blood count, liver function, renal function, plasma glucose, TAC, and polymerase chain reaction, were all assessed at baseline and at the end of the study. Clinical assessment included: hepato and/or splenomegaly, jaundice, palmar erythema, flapping tremors, spider naevi, lower-limb edema, and ascites. *N. sativa* was administered for three successive months at a dose of (450 mg three times daily). Clinical response and incidence of adverse drug reactions were assessed initially, periodically, and at the end of the study.

N. sativa administration significantly improved HCV viral load ($380,808.7 \pm 610,937$ vs. $147,028.2 \pm 475,225.6$, $p = 0.001$) and TAC (1.35 ± 0.5 vs. 1.612 ± 0.56 , $p = 0.001$). After *N. sativa* administration, the following laboratory parameters improved: total protein (7.1 ± 0.7 vs. 7.5 ± 0.8 , $p = 0.001$), albumin (3.5 ± 0.87 vs. 3.69 ± 0.91 , $p = 0.008$), red blood cell count (4.13 ± 0.9 vs. 4.3 ± 0.9 , $p = 0.001$), and platelet count (167.7 ± 91.2 vs. 198.5 ± 103 , $p = 0.004$). Fasting blood glucose (104.03 ± 43.42 vs. 92.1 ± 31.34 , $p = 0.001$) and postprandial blood glucose (143.67 ± 72.56 vs. 112.1 ± 42.9 , $p = 0.001$) were significantly decreased in both diabetic and non-diabetic HCV patients. Patients with lower-limb edema decreased significantly from baseline compared with after treatment [16 (53.30%) vs. 7 (23.30%), $p = 0.004$]. Adverse drug reactions were unremarkable except for a few cases of epigastric pain and hypoglycemia that did not affect patient compliance [5, 6].

3. Results and Discussion

✓ Mixture with bee products and herbs

Used in liver support therapy.

Ingredients: turmeric root, ginger root, artichoke leaves, nigella seed, BB, thistle honey.

✓ Turmeric *Curcuma longa*

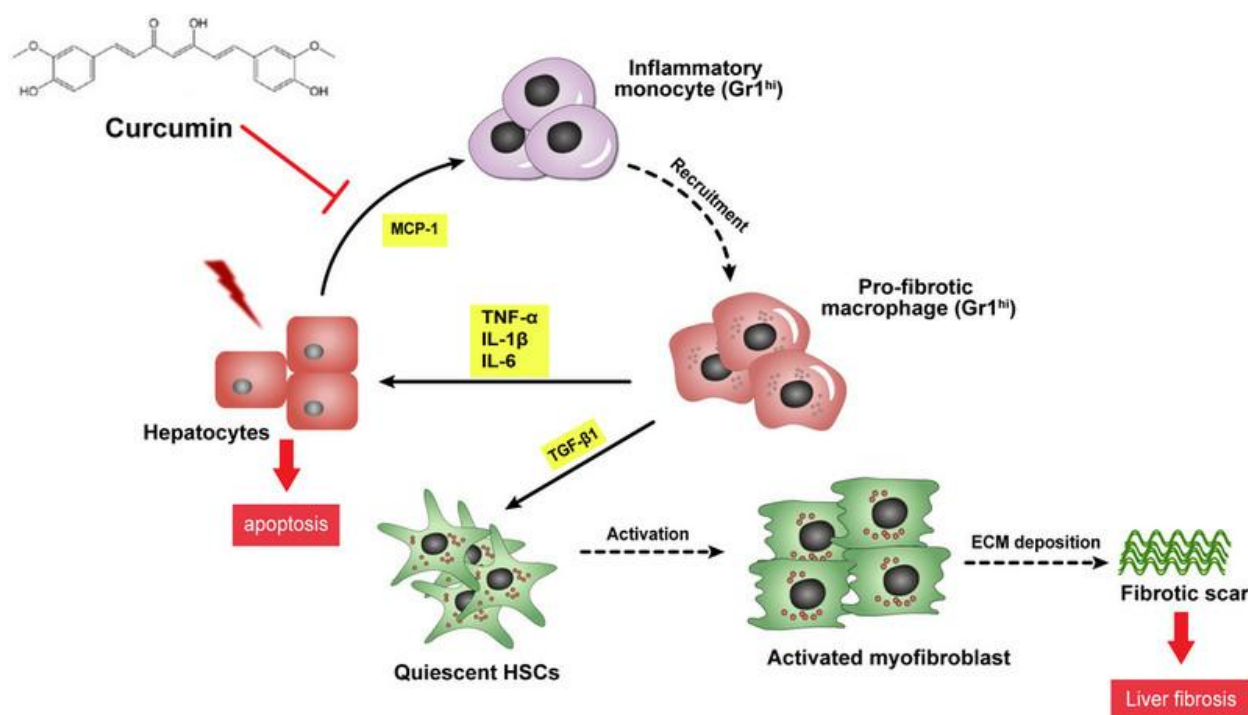


Fig. 1 Turmeric helps in removing toxins from the liver.

We have known for centuries the use of curcumin in turmeric to cleanse the liver. As is known, turmeric regenerates liver cells. Turmeric helps in removing toxins from the liver (Fig. 1). As Avicenna said, consuming turmeric is beneficial for the liver and facilitates digestion.

✓ ***Nigella Sativa***

Black seed protects the liver from some toxic heavy metals. Studies have clearly revealed that the black seed solution protects the liver on mice against a toxic substance called carbon tetrachloride. In addition, it has been stated that toxic substances have less effect on the tissue of the liver [7].

✓ ***Cynara scolymus***

Artichoke has been used for over 2,000 years to treat liver and gall bladder ailments, jaundice, in which “eyes and skin turn yellow”. It has been shown that the components found in artichokes, called flavonolignan (also known as cynarin), protect liver cells against alcohol, acetaminophen (tylenol), and the highly toxic tapeworm fungus [8].

✓ **BB**

It is a bee product that can be easily dissolved by the body. It reduces liver enzymes. Natural Lactic acid bacteria and bifidobacteria in it give it a natural probiotic feature.

✓ ***Zingiber officinale***

Thanks to the antioxidants it contains, ginger reduces triglyceride values and thus helps to reduce liver fat. It can reduce ALT, AST and GGT levels during steatohepatitis and hepatitis B. Results were available within 12 weeks. It is effective in basic therapy in non-alcoholic fatty liver disease [1].

✓ **Thistle honey**

Although thistle honey is an interesting type of honey, it is a very rare honey. It is common in Azerbaijani districts. Milk thistle honey, whose active ingredient is silymarin, creates a synergistic effect with other herbs. It is easier to absorb from the body and its agonist effect with other herbs, like other strained honey.

We could get results on these diseases using Herbal paste: Hepatitis B, Hepatitis C, NASH, ASH, cirrhosis (Tables 1 and 2).

Table 1 Effects of Herbal paste on ALT—one of the liver enzymes.

Different groups of liver patients	Users of herbal paste	Patients
Chronic hepatitis B	31 U/I	62 U/I
Non-alcoholic steatohepatitis	40 U/I	99 U/I
Alcoholic hepatitis	113 U/I	208 U/I
Liver cirrhosis	100 U/I	164 U/I

Number of patients for the study: 44 patients; Period of the study: 8 weeks; The daily dose: 15 kg/mg, 3 times.

Table 2 Effects on the liver size in case of steatohepatitis.

Patients with liver lubrication	Users of herbal paste	Patients
Nonalcoholic steatohepatitis	143 mm grade I	169 mm grade II
Alcoholic steatohepatitis	155 mm grade II	195 mm grade III

Number of patients for the study: 33 NASH and 36 ASH; Period of the study: 12 weeks; the daily dose: 20 kg/mg, 3 times.

3.1 Other Effects of the Herbal Mixture

Antioxidant effect on toxic hepatitis was damaged by long-term chemical therapies. Results due to liver cirrhosis and the lactobacilli, are intestinal disorder (diarrhea-constipation). Regulation of loss of appetite is due to containing flavonoids and minerals.

(1) Contraindications

Active stomach ulcer (bleeding), acute intestinal infection, lower gastrointestinal bleeding diseases, organ failure due to diabetes mellitus.

(2) Using Herbal paste with medicines

When it was used with Tenofovir (for Hepatitis B), it took away the side effects of the drug. It was used with Sofosbuvir, Ledipasvir, Daclatasvir (for Hepatitis C) and positive effects were experienced on ALT and AST. It caused diarrhea when it was used with ursodeoxycholic acid.

(3) Goals related to Herbal paste

We started research on other liver diseases and cancer with the Japanese scientists. To start production abroad. To start researches together with a number of countries to highlight the cooperation of phytotherapy and apitherapy. Researching the unknown effects and side effects of bee products to reach conclusions.

(4) Herbal paste

It can be considered possible to be used in pregnancy, except for intestinal infections. Children over 1 year old can use it. Chronic patients can use it alongside drugs.

References

- [1] Rahimlou, M., Yari, Z., Hekmatdoost, A., Alavian, S. M., and Keshavarz, S. A. 2016. "Ginger Supplementation in Nonalcoholic Fatty Liver Disease: A Randomized, Double-Blind, Placebo-Controlled Pilot Study." *Hepat Mon* 16 (1): e34897.
- [2] Mollazadeh, H., and Hosseinzadeh, H. 2014. "The Protective Effect of *Nigella sativa* against Liver Injury: A Review." *Iran J Basic Med Sci* 17 (12): 958-66.
- [3] Colak, E., Ustuner, M. C., Tekin, N., Colak, E., Burukoglu, D., Degirmenci, I., and Gunes, H. V. 2016. "The Hepatocurative Effects of *Cynara scolymus* L. Leaf Extract on Carbon Tetrachloride-Induced Oxidative Stress and Hepatic Injury in Rats." *Springerplus* 5: 216.
- [4] Sobral, F., Calhelha, R. C., Barros, L., Dueñas, M., Tomás, A., Santos-Buelga, C., Vilas-Boas, M., Isabel, C. F., and Ferreira, R. 2017. "Flavonoid Composition and Antitumor Activity of Bee Bread Collected in Northeast Portugal." *Molecules* 22 (2): 248.
- [5] Barakat, E. M. F., El Wakeel, L. M., and Hagag, R. S. 2013. "Effects of *Nigella sativa* on Outcome of Hepatitis C in Egypt." *World Journal of Gastroenterol* 19 (16): 2529-36.
- [6] Mansour-Ghanaei, F., Pourmasoumi, M., Hadi, A., and Joukara, F. 2019. "Efficacy of Curcumin/Turmeric on Liver Enzymes in Patients with Non-alcoholic Fatty Liver Disease: A Systematic Review of Randomized Controlled Trials." *Integrative Medicine Research* 8 (1): 57-61.
- [7] Dollah, M. A., Parhizkar, S., Latiff, L. A., and Hassan, M. H. B. 2013. "Toxicity Effect of *Nigella sativa* on the Liver Function of Rats." *Advanced Pharmaceutical Bulletin* 3 (1): 97-102.
- [8] Speroni, E., Cervellati, R., Govoni, P., Guizzardi, S., Renzulli, C., and Guerra, M. C. 2003. "Efficacy of Different *Cynarascolymus* Preparations on Liver Complaints." *Journal of Ethnopharmacol* 86 (2-3): 203-11.