

# Morphometric Examination of Radius

Seda Avnioğlu<sup>1</sup>, Seher Yılmaz<sup>2</sup> and Demet Ünalımsı<sup>3</sup>

1. Department of Anatomy, Faculty of Medicine, Alanya Alaaddin Keykubat University, Antalya 07000, Turkey

2. Department of Anatomy, Faculty of Medicine, Yozgat Bozok University, Yozgat 66100, Turkey

3. Department of Anatomy, Faculty of Medicine, Erciyes University, Kayseri 38039, Turkey

**Abstract:** Objective: The aim of this study was to contribute to the literature by making measurements on the dimensions of the dry radii. Methods: This study was carried out on 28 dry and radius bones. Bones were measured a total of 14 variables at the proximal end, trunk and distal end. Results: The mean radius length was 228.93 mm on the left side and 232.00 mm on the right side. Caput radii sagittal diameter: mean 21.5 mm on the left and 21.10 mm on the right. Caput radii transverse diameter: 20.36 mm on the left and 21.15 mm on the right. Circumferentia articularis circumferential: mean 665.80 mm on the left side and 69.24 mm on the right side. Incisura ulnaris width: the average depth of 14.83 mm on the left and 14.32 mm on the right. Incisura ulnaris depth: the mean value was 1.73 mm on the left side and 2.02 mm on the right side. Conclusion: This study provides a detail of the radius morphometric information about the proximal end, distal end and trunk. We think that our results are close to the information in the literature and will contribute to the literature.

**Keywords:** Radius, bone measurements, morphometry, anatomy

## 1. Introduction

Radius fractures are the most common fractures of the upper extremity. The aim of the treatment is to give the patient a painless and adequate wrist movement, to return the patient to pre-traumatic activity and to reduce the risk of degenerative changes and sequelae in the early and long term. Therefore, the materials to be used for interventions such as external fixation, plate-screw fixation or prosthesis applied during reduction must be compatible with the anatomy [1-3]. In order to achieve the best results of the treatment, it is necessary to apply the right method. Data about the morphology and morphometry of the radius are required for the best and right method [4]. In our study, we aimed to contribute to the literature by making measurements on the dimensions of the dry radii.

### 1.1 Anatomy

Radius is a long bone with two ends and a body on the outer side of the forearm bones. The upper face of the

protuberance called caput radii is covered with humerus and the surrounding part is covered with articular cartilage. The narrowed section at the bottom of the caput radii is called collum radii. Under the collum radii, there is a bulge called tuberositas radii, where the biceps brachii is attached. The body of radius has three sides and three faces. There is a membrane called interossea antebrachii between the radius and ulna facing sides. This membrane works especially for force transmission. The large lower end of the radius makes joint with os scaphoideum and os lunatum from the ulna and wrist bones. There are formations called processus styloideus radii on the outer side of the lower end and tuberculum dorsale on the posterior side. There are also grooves at the lower end where the tendons of the extensor muscles pass [5, 6].

## 2. Material and Method

This study was carried out on 28 dry and radius bones (12 left, 16 right) in Erciyes University Anatomy Department. Measurements were made using a digital caliper with a precision of 0.01 millimeters (mm) and

---

**Corresponding author:** Seda Avnioğlu, PhD, Asst Prof. Dr. Research Field: Anatomy, Morphometry, Stereology.

an inelastic tape measure. Data from both sides were measured symmetrically, and those with fractures, pathology, and abrasion of radius bones were not included. Measurements were made by a single person in order to avoid differences related to the measurement person and the results were recorded. Measurements were made on a total of 14 variables at the proximal end, trunk and distal end of the radius.

Measurement variables are as follows (Figs. 1-5):

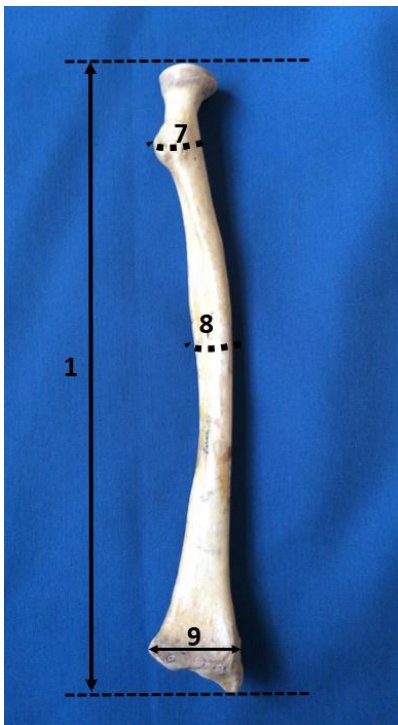

Fig. 1 Front view of radius.

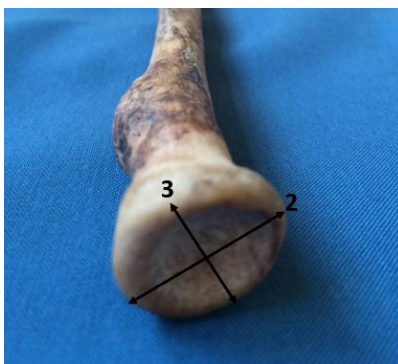


Fig. 2 Top view of caput radii.

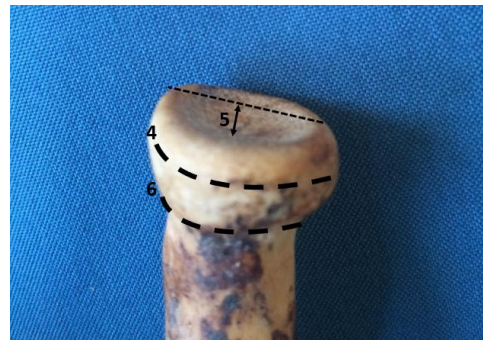

Fig. 3 Top-front view of caput radii.

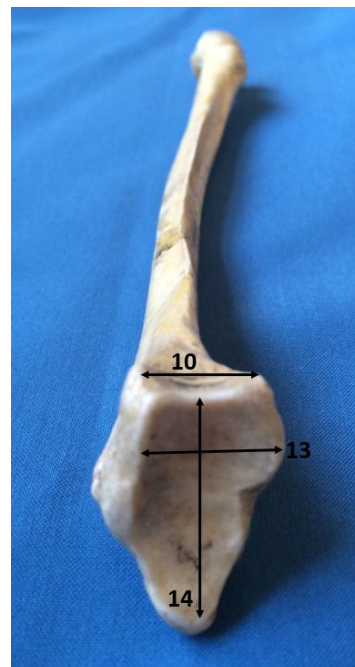


Fig. 4 Bottom view of radius.

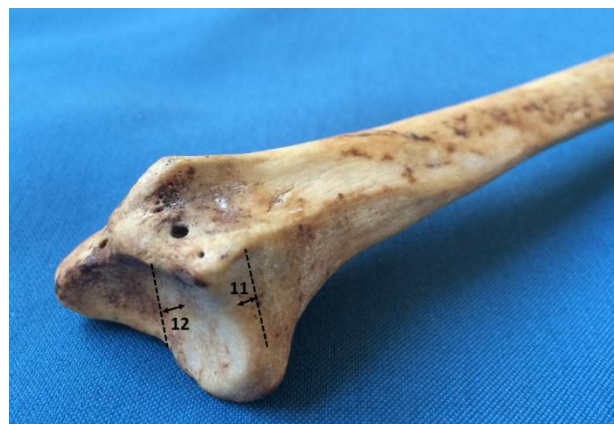

Fig. 5 Bottom-inside view of radius.

- (1) Length of radius;
- (2) Sagittal diameter of caput radii;
- (3) Transverse diameter of caput radii;
- (4) Circumferentia articularis surroundings;
- (5) Depth of fovea capitis radii;
- (6) The surroundings of collum radii;
- (7) The circumference of the body at the level of tuberositas radii;
- (8) Circumference of the body at the midpoint of the body;
- (9) Length of the widest space at the distal end of the radius;
- (10) Width of incisura ulnaris;
- (11) The depth of incisura ulnaris;
- (12) Depth of facies articularis carpalis;
- (13) Sagittal diameter of facies articularis carpalis;
- (14) Transverse diameter of facies articularis carpalis.

### 3. Results

The results of the morphometric measurements on 28 dry (12 left, 16 right) radius bones of unknown sex and age are shown in Table 1. According to the results in the table, the mean radius length was 228.93

mm on the left side and 232.00 mm on the right side. Caput radii sagittal diameter: mean 21.5 mm on the left and 21.10 mm on the right. Caput radii transverse diameter: 20.36 mm on the left and 21.15 mm on the right. Circumferentia articularis circumferential: mean 665.80 mm on the left side and 69.24 mm on the right side. Incisura ulnaris width: the average depth of 14.83 mm on the left and 14.32 mm on the right. Incisura ulnaris depth: the mean value was 1.73 mm on the left side and 2.02 mm on the right side (Table 1).

### 4. Discussion

Radius is a bone that is broken most commonly. Distal radius fractures are one of the most common types of fractures [7, 8]. Radial head and neck fractures represent approximately 1.7% to 5.4% of all fractures. Radial head fractures account for approximately one third of all elbow fractures [9]. To know the anatomy, morphology and morphometry of the radius increases the effectiveness of the treatment by providing the most accurate treatment techniques. For this reason, many morphometric studies have been done about radius.

**Table 1 Parameters and results of measurement on the radius bone.**

Parameters	Minimum (mm)	Maximum (mm)	Mean (mm)
Length of radius	Left: 199.44	Left: 252.34	Left (N: 12): 228.93
	Right: 208.85	Right: 259.30	Right (N: 16): 232.00
Sagittal diameter of caput radii	Left: 17.75	Left: 25.49	Left (N: 12): 21.52
	Right: 17.67	Right: 24.55	Right (N: 16): 21.10
Transverse diameter of caput radii	Left: 17.65	Left: 23.74	Left (N: 12): 20.36
	Right: 17.38	Right: 24.34	Right (N: 16): 21.15
Circumferentia articularis surroundings	Left: 55.46	Left: 79.67	Left (N: 12): 65.80
	Right: 54.82	Right: 88.47	Right (N: 16): 69.24
Depth of fovea capitis radii	Left: 1.07	Left: 2.52	Left (N: 12): 1.90
	Right: 1.21	Right: 2.37	Right (N: 16): 1.88
The surroundings of collum radii	Left: 41.91	Left: 70.85	Left (N: 12): 50.32
	Right: 35.47	Right: 59.37	Right (N: 16): 50.04
The circumference of the body at the level of tuberositas radii	Left: 40.71	Left: 65.75	Left (N: 12): 51.41
	Right: 47.71	Right: 65.28	Right (N: 16): 54.71
Circumference of the body at the midpoint of the body	Left: 34.40	Left: 53.63	Left (N: 12): 42.57
	Right: 41.12	Right: 56.27	Right (N: 16): 47.69
Length of the widest space at the distal end of the radius	Left: 28.26	Left: 36.96	Left (N: 12): 32.88
	Right: 27.51	Right: 38.03	Right (N: 16): 32.65
Width of incisura ulnaris	Left: 12.88	Left: 17.07	Left (N: 12): 14.83
	Right: 10.87	Right: 19.82	Right (N: 16): 14.32
The depth of incisura ulnaris	Left: 0.44	Left: 2.65	Left (N: 12): 1.73
	Right: 0.82	Right: 3.32	Right (N: 16): 2.02

Gupta et al., Gasse et al. and Giannicola et al. [10-12] found the length of radius as 23.5 cm, 22.9 cm and 22.1 cm, respectively. Prithishkumar et al. [13] found the length of left and right radius as 24.4 cm and 24.2 cm, respectively. We got value as 22.89 cm on left radius, 23.2 cm on right radius in our study.

Gupta et al., Puchwein et al. and Captier et al. [10, 14, 15] found the mean sagittal diameter of the radial head at its widest part as 19.1 mm, 21.5 mm, 23 mm and 21.6 mm, respectively, and in the transverse plane as 18.5 mm, 22.4 mm and 2.1 mm, respectively. Giannicola et al. [12] found the maximum diameter value is 21.5 mm, minimum diameter value is 20.8 mm. In our study, we got the values in sagittal diameter as 21.5 mm and 21.1 mm on left and right radius, respectively. The mean value of transverse diameter is 20.3 mm on left radius and 21.1 mm on right radius in our study. Puchwein et al. measured the values on CT scan and we did it on dry bone.

Captier et al. [15] measured the radius neck mediolateral diameter as 14.4 mm. Koslowsky et al. [16] studied the intramedullary canal anatomy of the radial neck for radial head prostheses. They used for the measuring 40 macerated proximal radii using X-rays and Optosil imprints of the intramedullary canal. They found the inner diameter of the radial neck value is 9.7 mm on X-ray, 11.6 mm on Optosil imprint [15, 16]. In our study, we measured the circumference of the radius neck and found that it was 50.32 mm in the left and 50.04 mm in the right.

Gupta et al. and Swieszkowski et al. [10, 17] found the mean depth of articular facet as 1.9 mm. Lalone et al. [18] used CT images and found the depth as 2mm. We got the value as 1.9 mm on left radius, 1.8 mm on right radius in our study.

Swieszkowski et al. [17] and Kuhn et al. [19] found the mean diameter of radius head as 23.36 mm and 24.8 mm. Swieszkowski et al. studied on fresh-frozen cadaver, Kuhn et al. studied on CT images. In our study, we found as 21.52 mm in the left radius and 21.1 mm in the right radius. Transverse diameter was

20.36 mm on the left and 21.15 mm on the right. In addition, Kuhn et al. [19] reported that the transverse diameter was longer than the sagittal diameter. In our study, we found that the transverse diameter was longer than the sagittal diameter.

Kuhn et al. [19] measured the diameter of tuberositas radii as 18.5 mm. In our study, we measured the circumference at the level of tuberositas radii and found that the mean value of the left radius was 51.41 mm and the mean value of the right radius was 54.71 mm.

Kamal et al. [20] described the sigmoid notches of the radius and used 44 fresh-frozen cadavers. The deepest point of the notch was 3.65 mm. In our study, we measured 1.73 mm on the left radius and 2.02 mm on the right radius.

Zumstein et al. [21] and Kwon et al. [22] measured the volar surface width of radius on cadaver CT images. They define the volar surface width as the length of a line drawn on the volar surface of the radius from the ulnar to the radial margin, perpendicular to the central axis of the distal radius. Zumstein et al. [21] and Kwon et al. [22] found as 37 mm and 30 mm, respectively. We did not make such a definition in our study. Aldemir et al. [23] performed a morphometric study of fossa lunata. They measured the depth, transverse and sagittal diameters of the lunate fossa using the Microscribe-G2X from the MicroScribe G series in 50 right, 50 left adult dry radius bones. The mean value of sagittal diameter of the lunate fossa was found as 19.65 mm on the left, 18.79 mm on the right. The value of transverse diameter was found as 11.38 mm on the left and 11.1 mm on the right. In our study, we measured the transverse and sagittal diameter of the distal articular surface. We found the mean value of transverse and sagittal diameter as 27.56 mm on the left, 26.66 mm on the right and 17.96 mm on the left, 16.34 mm on the right, respectively.

## 5. Conclusion

In the study provided morphometric information about the proximal end, distal end and trunk of the radius. We think that our results are close to the information in the literature and will contribute to the literature.

## References

- [1] Uludağ, A., Tosun, H. B., and Serbest, S. 2015. "Erişkin Radius ve Ulna Kırıkları." *Adıyaman Üniv. Sağlık Bilimleri Dergisi*. 1(2): 111-21.
- [2] Kayalar, M., and Gürbüz, Y. 2014. "Radius başı kırıklarının tedavisi." *TOTBİD Dergisi* 12:57-71.
- [3] Meena, S., Sharma, P., Sambharia, A. K., and Dawar, A. 2014. "Fractures of Distal Radius: An Overview." *J Family Med Prim Care* 3 (4):325-32.
- [4] Güdemez, E., Uludağ, S., and Ataker, Y. 2014. "Distal radius kırıklarına genel bakış ve konservatif tedavisi." *TOTBİD Dergisi* 12: 177-93.
- [5] Arıncı, K., and Elhan, A. 2006. *Anatomi*. 4th ed. Ankara: Güneş Kitabevi, 10.
- [6] Ozan, H. 2014. *Anatomi*. 3rd ed. Ankara: Klinisyen Tıp Kitabevleri, 14-5.
- [7] Oppermann, J., Wacker, M., Stein, G., Springorum, H. P., Neiss, W. F., Burkhart, K. J., Eysel, P., and Dargel, J. 2014. "Anatomical Fit of Seven Different Palmar Distal Radius Plates." *Arch Orthop. Trauma Surg*. 134(10): 1483-9.
- [8] Tordjman, D., Hinds, R. M., Yang, S. S., Capo, J. T. 2018. "Radial Shaft Convergence in Distal Radius Fractures: Diagnosis and Treatment." *Tech Hand up Extrem Surg*. 22(1): 19-25.
- [9] Caputo, A. E., Mazzocca, A. D., and Santoro, V. M. 1998. "The Nonarticulating Portion of the Radial Head: Anatomic and Clinical Correlations for Internal Fixation." *J Hand Surg Am*. 23(6): 1082-90.
- [10] Gupta, C., Kalthur, S. G., Malsawmzuali, J. C., and D'souza, A. S. 2015. "A Morphological and Morphometric Study of Proximal and Distal Ends of Dry Radii with Its Clinical Implications." *Biomed J* 38(4):323-8.
- [11] Gasse, N., Lepage, D., Pem, R., Bernard, C. M., Lerais, J., Garbuio, P., and Obert, L. 2011. "Anatomical and Radiological Study Applied to Distal Radius Surgery." *Surg Radiol Anat* 33:485-90.
- [12] Giannicola, G., Manauzzi, E., Sacchetti, F. M., Greco, A., Bullitta, G., Vestri, A., and Cinotti, G. 2012. "Anatomical Variations of the Proximal Radius and Their Effects on Osteosynthesis." *J Hand Surg Am*. 37(5): 1015-23.
- [13] Prithishkumar, I. J., Francis, D. V., Nithyanand, M., Verghese, V. D., and Samue, P. 2012. "Morphometry of the Distal Radius—An Osteometric Study in the Indian Population." *Indian Journal of Basic & Applied Medical Research* 3(1): 166-71.
- [14] Puchwein, P., Heidari, N., Dorr, K., Struger, L., and Pichler, W. 2013. "Computer-Aided Analysis of Radial Head Morphometry." *Orthopedics* 36: 51-7.
- [15] Captier, G., Canovas, F., Mercier, N., Thomas, E., and Bonnel, F. 2002. "Biometry of the Radial Head: Biomechanical Implications in Pronation and Supination." *Surg Radiol Anat* 24: 295-301.
- [16] Koslowsky, T. C., Beyer, F., Germund, I., Mader, K., Jergas, M., and Koebke, J. 2007. "Morphometric Parameters of the Radial Neck: An Anatomical Study." *Surg Radiol Anat* 29(4): 279-84.
- [17] Swieszkowski, W., Skalski, K., Pomianowski, S., and Kedzior, K. 2001. "The Anatomic Features of the Radial Head and Their Implication for Prosthesis Design." *Clin Biomech(Bristol, Avon)* 16:880-7.
- [18] Lalone, E. A., Deluce, S. R., Shannon, H., King, G. J. W., and Johnson, J. A. 2017. "Design of Anatomical Population-Based and Patient-Specific Radial Head Implants." *J Hand Surg Am*. 42(11): 924.e1-11.
- [19] Kuhn, S., Burkhart, K. J., Schneider, J., Muelbert, B. K., Hartmann, F., Mueller, L. P., and Rommens, P. M. 2012. "The Anatomy of the Proximal Radius: Implications on Fracture Implant Design." *J Shoulder Elbow Surg* 21(9):1247-54.
- [20] Kamal, R. N., Leversedge, F., Ruch, D. S., Mithani, S. K., Cotterell, I. H. F., and Richard, M. J. 2018. "The Sigmoid Notch View for Distal Radius Fractures." *J Hand Surg Am* 43(11):1038.e1-5.
- [21] Zumstein, M. A., Hasan, A. P., McGuire, D. T., Eng, K., and Bain, G. I. 2013. "Distal Radius Attachments of the Radiocarpal Ligaments: An Anatomical Study." *J Wrist Surg* 2(4): 346-50.
- [22] Kwon, B. C., Lee, J. K., Lee, S. Y., Hwang, J. Y., and Seo, J. H. 2018. "Morphometric Variations in the Volar Aspect of the Distal Radius." *Clin Orthop Surg* 10(4): 462-7.
- [23] Aldemir, C., Önder, M., Doğan, A., Duygun, F., and Oğuz, N. 2015. "Lunat fossanın morfometrik anatomik çalışması ve klinik önemi." *Joint Diseases and Related Surgery* 26(1): 27-30.